

Feasibility of Radioactive Embolization of Intracranial Aneurysms Using ^{32}P -Implanted Coils

Jean Raymond, MD; Philippe Leblanc, PhD; Anick Lambert, MSc; Stavros A. Georganos, MD; François Guilbert, MD; Christian Janicki, PhD; Sjoerd Roorda, PhD

Background and Purpose—Beta radiation can prevent recanalization after embolization. Our goal was to assess the feasibility of endovascular treatment of intracranial aneurysms using coils of a predetermined activity of ^{32}P per centimeter.

Methods—We studied the total length of coils deployed into 357 intracranial aneurysms. Aneurysmal volumes were estimated using 3 mathematical models. We simulated that coils were implanted with $0.26 \mu\text{Ci}/\text{cm}$ of ^{32}P , calculated resulting volumetric activities, and compared them with “effective” levels derived from experimental data and “safe” levels prescribed for the clinical use of ^{32}P in cystic craniopharyngiomas.

Results—Effective activities would have been reached in 92% to 98% of lesions had the coils been radioactive at the time of treatment.

Conclusion—Radioactive coil embolization of aneurysms is feasible in most patients. (*Stroke*. 2003;34:1035-1037.)

Key Words: aneurysm ■ endovascular therapy ■ radiation

Local beta radiation can prevent recanalization after coil embolization of arteries or aneurysms.¹ We have proposed treating aneurysms with coils ion-implanted with a predetermined linear activity of ^{32}P .¹ An “effective linear” activity of $0.13 \mu\text{Ci}/\text{cm}$ of coil has shown an 88% efficacy in preventing recanalization.¹ The interventionist would then attempt to fill the aneurysm with coils implanted with at least that level of activity of ^{32}P , without exceeding total activities prescribed by the historical use of colloidal ^{32}P in craniopharyngiomas.²

To assess the feasibility of this protocol, we reviewed aneurysms treated with standard coils and calculated the resulting activities per volume of aneurysms had the coils been radioactive.

Methods

We retrospectively studied aneurysms that were treated by endosaccular coiling and prospectively entered into a database from 1992 to 2001. Partially thrombosed aneurysms and interventions that were prematurely interrupted because of complications or for which records were incomplete were excluded from analysis. There were 357 aneurysms in 341 patients 25 to 86 years of age (mean age 54 ± 12). Most patients were female (73.6%). The most frequent lesions were basilar bifurcation (103; 28.9%) and ophthalmic carotid aneurysms. Initial angiographic results, classified as previously described,³ were the following: complete occlusions in 130 (36.4%), residual necks in 181 (50.7%), and residual aneurysms in 46 (12.9%) cases.

The total length of coils deployed within each aneurysm was recorded without distinction between calibre 10 and 15 coils. Volumes were estimated according to the formulas

$$\begin{aligned}V_{\text{ellipsoid}} &= \frac{4}{3} \cdot \pi \cdot \left(\frac{a_L}{2}\right) \cdot \left(\frac{a_S}{2}\right) \cdot \left(\frac{a_L + a_S}{4}\right) \\V_{\text{cylinder}} &= \pi \cdot \left(\frac{a_S}{2}\right)^2 \cdot a_L \\V_{\text{sphere}} &= \frac{4}{3} \cdot \pi \cdot \left(\frac{a_L}{2}\right)^3\end{aligned}$$

that assimilate aneurysms to spheres, cylinders, or ellipsoids and where a_L and a_S are the long and short axes of the aneurysm, respectively. Dimensions were estimated using the size of the first coil as a reference. The “effective” dose per volume was extracted from previously published animal data¹; the arterial length occupied by deployed coils was measured as 10.62 ± 2.14 mm. Arteries that remained occluded 3 months after radioactive coil embolization were thus assimilated to 10×3 -mm cylindrical aneurysms. An effective activity of $0.13 \mu\text{Ci}/\text{cm}$ ^{32}P was selected because it was as effective as $0.4 \mu\text{Ci}/\text{cm}$ but significantly more effective than $0.10 \mu\text{Ci}/\text{cm}$.¹ Consequently, the volumetric activity found to be effective in the arterial occlusion model was $0.018 \mu\text{Ci}/\text{mm}^3$ ($1.3 \mu\text{Ci}/70 \text{mm}^3$). Two levels of linear activity were studied (Table). Assuming coils would be ion-implanted with activities that would permit a shelf life of 14 days (the half-life of the isotope), the higher activity ($0.26 \mu\text{Ci}/\text{cm}$) corresponds to double the effective linear activity. In addition, we estimated aneurysmal activities resulting from theoretical embolizations performed according to the data of Piotin et al⁴ on packing density with calibre 15 coils.

Colloidal ^{32}P has been used for years in cystic craniopharyngiomas.² Tables have been designed to prescribe the activity of ^{32}P to be

Received July 9, 2002; final revision received October 24, 2002; accepted October 24, 2002.

From the Department of Radiology (J.R., S.A.G., F.G.) and Research Centre (J.R., P.L., A.L.) of Centre Hospitalier de l'Université de Montréal; Department of Medical Physics (C. J.), McGill University Health Centre; and Physics Department (S.R.), Université de Montréal, Québec, Canada.

Correspondence to Jean Raymond, MD, Department of Radiology, Notre-Dame Hospital, 1560 Sherbrooke East, Suite M-8203, Montreal, Quebec, H2L 4M1, Canada. E-mail dr_jean_raymond@hotmail.com

© 2003 American Heart Association, Inc.

Stroke is available at <http://www.strokeaha.org>

DOI: 10.1161/01.STR.0000063140.00091.A6

Aneurysmal Dimensions, Coil Length, and Simulation of Radioactive Coil Embolization

Dimensions	Long Axis, mm	Short Axis, mm	Neck Width, mm
Mean	9.1	6.8	4.2
SD	±5.1	±4.0	±1.8
Range	3–28	2–24	1–12

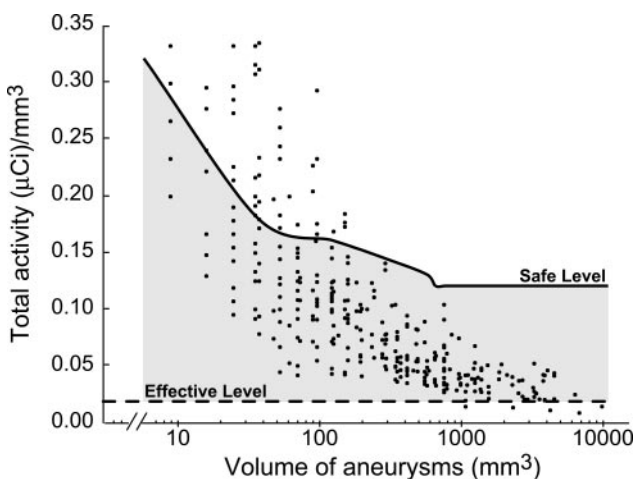
Volumes	Mean ± SD		
	$V_{\text{ellipsoid}}$	V_{sphere}	V_{cylinder}
Total coil length, cm	90 ± 109	90 ± 109	90 ± 109
Volume, mm ³	549 ± 1030	825 ± 1487	721 ± 1396
Coil length/volume, cm/mm ³	0.414 ± 0.319	0.291 ± 0.249	0.324 ± 0.251
Activity/volume, $\mu\text{Ci}/\text{mm}^3$ (for 0.13 $\mu\text{Ci}/\text{cm}$ coils)	0.054 ± 0.041	0.038 ± 0.032	0.042 ± 0.033
% of cases above 0.018 $\mu\text{Ci}/\text{mm}^3$	88%	69%	76%
Activity/volume, $\mu\text{Ci}/\text{mm}^3$ (for 0.26 $\mu\text{Ci}/\text{cm}$ coils)	0.108 ± 0.083	0.076 ± 0.065	0.084 ± 0.065
% of cases above 0.018 $\mu\text{Ci}/\text{mm}^3$	98%	92%	96%

injected according to cyst volumes. To ensure the safety of radioactive coil embolization of aneurysms, we have used these tables to arbitrarily set the “maximum activities” to be inserted according to size of lesions. An error has occurred in these tables that has since been corrected.⁵

Aneurysmal values have been doubled; because ion implantation of ³²P is limited to half the coil surface, and because of platinum attenuation, only half the activity contributes to the dose to tissues (exact numbers, based on Monte Carlo simulations, will be the subject of another publication).

Results

Results are summarized in the Table. Had coils been ion-implanted with 0.26 $\mu\text{Ci}/\text{cm}$ of ³²P, 92% to 98% of lesions (according to the ellipsoid model) would contain volumetric activities shown to be effective in preventing recanalization in animal experiments. The Figure illustrates the relationship



Theoretical aneurysmal activities in relation to volumes. Shown are aneurysmal activities per cm had the platinum coils been ion-implanted with 0.26 $\mu\text{Ci}/\text{cm}$ of ³²P. Each point represents one aneurysm. Volumes were estimated using the ellipsoid model. Dashed line represents volumetric activity shown effective in the arterial occlusion model (0.018 $\mu\text{Ci}/\text{mm}^3$)¹; solid line, safe activity level, derived from the use of colloidal ³²P in cystic craniopharyngiomas^{2,5}; and shaded area, the therapeutic window.

between activities per mm³ and aneurysmal volumes, as well as the effective and “safe” limits, had the coils been implanted with 0.26 $\mu\text{Ci}/\text{cm}$.

Only in small lesions (<100 mm³ or <6 mm in both axes) would the total activity exceed arbitrary maximal values. For larger aneurysms (>1000 mm³), the packing density decreases to such an extent that it becomes difficult to reach the effective volumetric activity.

The relationship between the length of coils deployed into in vitro aneurysms and the volume of lesions is $\approx 250 \text{ cm}/\text{cm}^3$ according to data from Piotin et al.⁴ Assuming 0.13 $\mu\text{Ci}/\text{cm}$, the resulting activity, 0.0325 $\mu\text{Ci}/\text{mm}^3$, is well above the effective activity (0.018 $\mu\text{Ci}/\text{mm}^3$). Assuming 0.26 $\mu\text{Ci}/\text{cm}$, the resulting activity (0.065 $\mu\text{Ci}/\text{mm}^3$) is well below our arbitrary safe level (0.12 $\mu\text{Ci}/\text{mm}^3$ in lesions >1000 mm³).

Discussion

In situ beta radiation is a new strategy designed to prevent recanalization after endovascular treatment.¹ Although exact mechanisms responsible for this effect of radiation remain to be determined, we believe this phenomenon should be exploited to decrease recurrences after endovascular treatment of intracranial aneurysms. Because the distribution of deployed coils remains impossible to predict or to determine with precision, the most accurate way of delivering radiation is to use the coil itself as the source of beta particles, by ion implantation of a predetermined linear activity of ³²P per centimeter of coil. Because beta particles emitted from ³²P have a limited penetration (70% of the energy is deposited within 1 mm), this strategy limits radiation exposure to tissues in the immediate vicinity of coils. Because ion implantation renders platinum coils radioactive without any mechanical alteration of the device,¹ endovascular treatment can be performed with the same security as the current treatment and using the expertise that interventionists have developed over the past 10 years.

Before submitting patients to a radiation treatment, a target tissue and a therapeutic dose should be determined. This cannot be done in a conventional fashion with in situ beta

radiation and current embolic agents. The exact position of the source in relation to the target tissue is unknown, and conventional dosimetric calculations are impossible. The target tissue is likely the clot that forms after coil embolization,¹ but we cannot exclude an effect on the endothelial lining as a potential important factor.⁶

To ensure the same safety and efficacy as standard coil interventions, a combination of standard and radioactive coils may be appropriate in certain circumstances. Thus, linear activities must be converted into volumetric activities. This work has shown that, had the coils been ion-implanted with 0.26 $\mu\text{Ci}/\text{cm}$, 92% to 98% of 357 lesions would have reached effective therapeutic levels according to preclinical data. The methods implemented in this study to estimate aneurysmal volumes were approximate. Nevertheless, effective activities could be reached in most patients, regardless of the model used, including a spherical model that grossly overestimates volumes. In clinical practice, the use of validated measurement software could improve the accuracy of volumetric data.

We must emphasize that the activity-effect relationship was previously determined using an arterial model.¹ Activities necessary to prevent recanalization of aneurysms may differ.

Whereas the target tissue has not been determined with certainty, tissues to be spared are well known; these are the brain and cranial nerves in the vicinity of the aneurysm. Fortunately, beta radiation with ³²P has been used in benign intracranial lesions and safe levels of activities have previously been published.² The current study shows that maximal activities could be reached in small lesions embolized with “high-activity” coils (0.26 $\mu\text{Ci}/\text{cm}$; Figure). Therefore, the intervention should be planned accordingly, using nonradio-

active or low-activity coils. Conversely, effective therapeutic levels are more difficult to reach in large lesions (Figure), and higher activities could be implanted onto large coils.

Conclusion

Radioactive coil embolization of aneurysms using a predetermined activity of ³²P per centimeter of platinum is theoretically feasible in most patients. A randomized clinical study is needed to assess its value in improving long-term results of endovascular treatment.

Acknowledgments

This work was supported by grants from the Canadian Institutes of Health Research and partially by Valorisation Recherche Québec and Fondation des Maladies du Cœur du Québec.

References

1. Raymond J, Leblanc P, Desfaits AC, Salazkin I, Morel F, Janicki C, Roorda S. In situ beta radiation to prevent recanalization after coil embolization of cerebral aneurysms. *Stroke*. 2002;33:421–427.
2. Shapiro B, Fig LM, Gross MD. Intracavitary therapy of craniopharyngiomas. *Q J Nucl Med*. 1999;43:367–374.
3. Roy D, Milot G, Raymond J. Endovascular treatment of unruptured aneurysms. *Stroke*. 2001;32:1998–2004.
4. Piotin M, Mandai S, Murphy KJ, Sugiu K, Gailloud P, Martin JB, Rufenacht DA. Dense packing of cerebral aneurysms: an in vitro study with detachable platinum coils. *AJNR Am J Neuroradiol*. 2000;21:757–760.
5. Janicki C, Seuntjens J. Evaluation of the dose to the cyst wall and to surrounding tissues in P-32 and Y-90 radiocolloids treatments of cysts using the dose-point-kernel and Monte Carlo methods. *Med Phys*. 2002;29:1203–1207.
6. Raymond J, Sauvageau E, Salazkin I, Ribourtout E, Gevry G, Desfaits AC. Role of the endothelial lining in persistence of residual lesions and growth of recurrences after endovascular treatment of experimental aneurysms. *Stroke*. 2002;33:850–855.