

Endovascular Treatment of Intracranial Aneurysms With Radioactive Coils

Initial Clinical Experience

Jean Raymond, MD; Daniel Roy, MD; Philippe Leblanc, PhD; Sjoerd Roorda, PhD; Christian Janicki, PhD; Lysanne Normandeau, BSc; François Morel; Guylaine Gevry, BSc; Jean-Paul Bahary, MD; Miguel Chagnon, PhD; François Guilbert, MD; Alain Weill, MD

Background and Purpose—Endovascular treatment of intracranial aneurysms is safe and effective but is associated with angiographic recurrences. Beta radiation prevents recanalization after coil embolization in experimental models. We wanted to assess the feasibility of using radioactive coil embolization to improve long-term results of endovascular treatment.

Methods—Platinum coils were ion-implanted with 0.13 to 0.26 $\mu\text{Ci}/\text{cm}$ of ^{32}P . Forty-one patients aged 34 to 84 years with 44 aneurysms with a high propensity for recurrences were included. Radioactive coils were introduced into aneurysms to reach a target volumetric activity of 0.018 $\mu\text{Ci}/\text{mm}^3$. Nonradioactive coils were also used to ensure the same safety and the same angiographic results as the standard procedure. Angiographic results, procedure-related complications, and neurological events during follow-up were recorded. Angiographic follow-up data are available in 36 lesions 6 months after treatment.

Results—Forty of 44 aneurysms (91%) could be treated with radioactive coils. Target activities could be reached in 88% of lesions that could actually be coiled (35/40). Total activities ranged from 1.72 to 80.9 μCi , for a mean of $20.13 \pm 20.80 \mu\text{Ci}$. Procedure-related complications occurred in 7% of patients. Initial angiographic results were satisfactory (complete occlusions or residual necks) in 75% of lesions. Angiographic recurrences occurred in 11 (31%) of patients followed, within the expected range for standard coils. There was no complication from beta radiation during a mean follow-up period of 10 months.

Conclusions—Radioactive coil embolization is feasible; target volumetric activities can be reached in most aneurysms considered for endovascular treatment. (*Stroke*. 2003;34:2801-2806.)

Key Words: cerebral aneurysm ■ cerebrovascular disorders ■ endovascular therapy ■ radiation

Endovascular treatment of intracranial aneurysms with platinum coils is safe and effective and can improve the outcome of patients with ruptured aneurysms.¹ The role of coil embolization of unruptured lesions remains to be determined, but a number of studies have shown its safety and its “quality of life effectiveness” compared with surgical clipping.^{2–5} Unfortunately, angiographic recurrences occur in approximately 20% to 40% of patients with long-term follow-up^{6–8} and may be responsible for subarachnoid hemorrhage during follow-up in <1% of patients.^{6–9} In situ beta radiation has been shown to prevent recanalization after coil embolization in animal models.^{10,11} Therefore, we proposed to attempt to improve long-term results of endovascular treatment using a radioactive coil strategy.^{10–12}

The purpose of this article is to report our initial experience with radioactive coil embolization of intracranial aneurysms. Our goals were to assess the feasibility of reaching the target activities shown to be effective in animal models and to verify whether there were any unexpected complications related to the use of ^{32}P coils.

Subjects and Methods

Patients

During a first phase of this feasibility trial, patients (n=12) were selected because (1) aneurysms were considered unsuitable for surgical treatment, and (2) they had already recurred after endovascular treatment, or (3) they presented lesions with characteristics associated with a high risk for recurrence (large and giant aneurysms or wide-neck aneurysms [>4 mm]). Inclusion criteria were then

Received May 12, 2003; final revision received June 26, 2003; accepted July 22, 2003.

From the Departments of Radiology (J.R., D.R., F.G., A.W.), Radio-Oncology (J-P.B.), Physics and Biomedical Engineering (L.N.), and Research Center (J.R., P.L., F.M., G.G.), Centre hospitalier de l'Université de Montréal (CHUM)–Notre Dame Hospital; Departments of Physics (S.R.) and Mathematics and Statistics (M.C.), University of Montreal; and Department of Medical Physics, McGill University Health Centre (C.J.), Montreal, Quebec, Canada.

Reprint requests to Jean Raymond, MD, Interventional Neuroradiology Research Laboratory, CHUM–Hôpital Notre-Dame, 1560 Sherbrooke St E, Room M-8203, Montreal, Quebec H2L 4M1, Canada. E-mail dr_jean_raymond@hotmail.com

© 2003 American Heart Association, Inc.

Stroke is available at <http://www.strokeaha.org>

DOI: 10.1161/01.STR.0000098651.14384.AB

widened to include any patients considered for endovascular treatment.

Calculation of Therapeutic Activities

Aneurysm dimensions were estimated with the first coil used as a reference. The volume of aneurysms was calculated according to an ellipsoid model.¹¹ In cases already presenting a recurrence, the volume was limited to the opacified portion of the aneurysmal sac. The target therapeutic activities to be introduced into each lesion were calculated with the following formula: target activity = $0.018 \mu\text{Ci} \times \text{volume of aneurysm in mm}^3$.¹¹

To ensure the safety of radioactive coil embolization of aneurysms, we adapted tables used to prescribe the activity of colloidal ³²P to be inserted in cystic craniopharyngiomas.^{11,13,14} These maximal activities were calculated as follows. Briefly, we have developed a dose calculation tool based on the Medical Internal Radiation Dosimetry formalism with *S* values evaluated at the voxel level.¹⁴ If it is assumed that the activity is distributed uniformly in a source voxel *h*, the average dose *D_k* in a target voxel *k* dose can be written as follows:

$$(1) \quad D_k = \sum_h \bar{A}_h S_{k \leftarrow h},$$

where \bar{A}_h is the cumulated and $S_{k \leftarrow h}$ is the *S* factor from source voxel *h* to target voxel *k*. The convolution kernel $S_{k \leftarrow h}$ is obtained by averaging the dose point kernel function $K(r-r')$ over the source voxel *h* and target voxel *k* according to the following

$$(2) \quad S_{k \leftarrow h} = \frac{1}{\Delta V^2} \int_h \int_k dV_h dV_k K(r-r').$$

The convolution in Equation 1 is done with the use of the discrete Fourier transforms convolution theorem and yields the dose *D_k* over the whole 3-dimensional voxel space. From this dose distribution, dose profiles and dose-volume histograms can be calculated over the aneurysm volume, surface, or margins.

Our calculation tool was benchmarked extensively against published data for dose around spheres of various sizes.¹⁵

Ion Implantation of Coils

³²P coils were produced as previously described¹⁰ on a dedicated radioactive ion implanter at the Université de Montréal. ³²P was purchased from Perkin Elmer Life Sciences and coils from Target Therapeutics. Coils were measured after implantation, identified, sterilized, and inserted into a Plexiglas box.

Coil Supply and Radiation Safety Issues

The typical radioactive coil kit consisted of 20 to 30 platinum coils, 14 to 2 mm in diameter, of caliber 0.015 for sizes ≥ 5 mm, and of caliber 0.010 for smaller coils, ion-implanted with 0.13 to 0.26 $\mu\text{Ci}/\text{cm}$. Personnel involved in the procedure were trained by the radiation safety officer in the appropriate handling of ³²P. There was no additional measure to the standard precautions in the handling of material in contact with body fluids that in effect also minimize risks of radioactive contamination. There is no need for special shielding because of the low levels of activity, poor penetration of beta rays, and short periods of manipulation of sheathed coils. Surfaces, linen, and waste were screened for the presence of radioactivity. Coil sheaths and pusher wires, as well as undetached coils, were stored in a second Plexiglas box, screened for radioactive contamination before disposal, and kept for decay if necessary. Coils that were deployed but not detached were counted after the procedure, and activities were compared with those found immediately after ion implantation. As another means of detecting leaching of ³²P from coils during clinical use, urinary collections were performed for 24 hours and counted in 4 patients treated with a total of 8, 10, 16, and 47 μCi of ³²P.

Endovascular Treatment

Patients and families were informed of the nature, goals, potential benefits, and risks of participating in the study and signed a written consent form approved by the Institutional Ethics Committee. The technique for endovascular treatment with platinum coils was exactly as described^{16,17} except that radioactive instead of standard coils were used if they were believed to be appropriate in caliber, size, and length. Physicians (J.R., D.R., A.W., F.G.) could always choose a nonradioactive coil from the inventory if they believed it would be safer, more effective, or more appropriate for each coil deposition. All procedures were performed with the patient under general anesthesia, with systemic heparinization, and with the use of a monoplane C-arm angiographic system without 3-dimensional reconstruction. Procedure-related complications were recorded immediately, and clinical complications were noted before discharge and 1 month after treatment. All patients had a CT scan 24 hours after the procedure to detect silent infarcts.

Angiographic Results

Angiographic follow-up studies were scheduled at 6 months in all patients actually treated with coils. Anatomic results were classified as previously published.^{2,17} Briefly, results were divided into 3 classes: (1) complete obliteration; (2) residual neck, defined as the persistence of any portion of the original defect of the arterial wall; and (3) residual aneurysm, defined as any opacification of the sac. At follow-up angiography, a recurrence was defined as any increase in the size of the remnant. The recurrence was qualified as major if its size would theoretically allow retreatment with coils.

Clinical Follow-Up

Further clinical follow-up data were collected during hospitalization for follow-up angiography or during visits at the outpatient clinic. Patients were graded according to the Glasgow Outcome Scale (GOS). Any new neurological episodes were noted.

Statistical Analysis

For each lesion of the present study, we calculated the probability of a recurrence according to its characteristics, using results of the logistic regression model obtained in a previous retrospective study on long-term results of endovascular treatment of aneurysms.⁸ From these probabilities, we established the predicted rate of recurrences. We also determined the 95% CI for the rate of recurrence actually observed.

Results

Patients and Aneurysms

The study included 41 patients aged 34 to 84 years, for a mean age of 57 ± 14 years. Most patients (80.5%) were women. They were treated electively (59%) or during the acute phase after subarachnoid hemorrhage (42%). Patients treated electively presented with mass effect (7; 17%), presented with headaches (5; 12%), or had a recurrence of a previously unruptured (1; 2%) or ruptured aneurysm (10; 24%) or previously bled from another aneurysm (1; 2%). Patients and aneurysms are summarized in Table 1. Most patients (38/41) were treated for 1 lesion, while 3 patients had 2 aneurysms treated with radioactive coils.

Aneurysms (n=44) were most frequently basilar bifurcation (34%), posterior communicating (16%), ophthalmic carotid (14%), and anterior communicating artery aneurysms (11%).

Lesions were 4 to 30 mm in size (mean, 10.4 ± 5.8 mm), with a mean neck diameter of 4.7 ± 1.7 mm. Five lesions (11%) were giant (>25 mm). In 12 cases (27%), the lesion

TABLE 1. Summary of Patients and Aneurysms

Age	SAH/Symptoms	Aneurysm Location	Maximum Size, mm	Length ³² P Coils, cm	Length Nonradioactive Coils, cm	Packing Density, %	Total Activity, μ Ci	Volumic Activity, μ Ci/mm ³	Immediate Results	Complications	Follow-Up Results	Outcome GOS
75	Mass effect	SCA	25	375	190	11	72	0.012	RA	Progressive mass effect	RA	V
34	Headache	PCA	20	389	210	22	71	0.024	CO	Stroke	RN	IV
79	Recurrent SAH†	P.Com	25	252	130	7	51	0.009	RN	No	...	III
45	Headache	BB	10	30	0	F	Transient cort. blindness	...	I
34	SAH	PCA	10	53	0	7	10	0.027	RA	No	...	III
48	SAH	Ophit	12	59	16	11	11	0.032	CO	No	CO	I
73	Headache	P.Com	14*	230	0	21*	32	0.028	RN	No	RN	I
42	SAH	BB	5	0	34	...	0	...	CO	Asympt. clot	CO	I
49	Previous SAH†	P.Com	7	70	10	45	14	0.098	RN	Bleeding 5M/surgery	RA	II
41	SAH	BB	10	70	0	13	10	0.022	RN	No	CO	I
53	Previous SAH†	BB	10	114	0	28	24	0.064	RN	No	RN	I
53	Mass effect	PICA	16*	240	0	17*	35	0.025	RN	No	RA	I
64	SAH	A.Com	14	0	0	0	0	...	F	No	...	II
69	Previous SAH†	BB	8	146	0	38	21	0.078	RN	No	RN	I
74	Previous SAH†	CB	12	109	0	21	33	0.048	CO	No	RN	I
		Peric	6	45	0	26	7	0.083	RA	No	RA	
52	Previous SAH†	A.Com	4	0	0	0	0	...	F	No	...	I
43	SAH	A.Com	10	76	20	29	11	0.044	CO	No	CO	I
82	SAH	MCA	5	31	6	39	3	0.058	CO	No	RN	I
80	SAH	P.Com	12	119	0	14	23	0.034	RA	No	RA	I
49	SAH	BB	9	93	6	31	17	0.065	RN	No	RN	III
37	Previous SAH†	P.Com	6	30	0	23	7	0.107	RN	No	CO	I
		BB	4	8	0	18	2	0.081	RA	Asympt. clot	CO	
69	Headache	CB	4*	16	0	36*	2	0.103	RN	No	RN	I
46	SAH	BB	20	142	0	6	47	0.019	CO	No	RN	II
37	SAH	Ophit	12	46	36	13	10	0.024	CO	No	CO	I
54	Mass effect	Ophit	8	61	29	21	17	0.062	CO	Asympt. stroke	CO	I
		Bb	4	16	4	45	2	0.113	CO	No	CO	
84	SAH	A.Com	16	194	0	17	32	0.026	RA	No	RA	I
59	Previous SAH†	Ophit	6	26	6	25	4	0.056	RN	No	RN	I
49	Mass effect	SCA	5*	16	6	59*	3	0.150	RN	No	CO	I
60	SAH	BB	14	60	0	8	10	0.014	CO	No	CO	I
56	Previous SAH†	Peric	4	12	2	31	2	0.096	RN	No	RA	I
56	Mass effect	A.Com	8	0	83	...	0	...	RA	Asympt. clot	RA	I
72	Mass effect	Ophit	16*	152	60	13*	18	0.010	RN	No	RN	I
56	SAH	BB	7	56	0	28	9	0.064	CO	No	CO	III
73	Previous SAH†	P.Com	5	16	0	17	4	0.076	RN	No	RN	I
43	SAH	CB	5	8	0	12	2	0.068	CO	No	CO	I
49	SAH	BB	12	115	30	22	23	0.039	RN	No	CO	I
70	Headache	Ophit	5	24	8	33	2	0.052	RN	No	RN	I
66	Mass effect†	BB	9*	184	156	97*	45	0.019	RN	No	...	I
50	SAH	BB	12	112	0	22	10	0.029	CO	No	CO	I
61	Asympt. recurrence†	P.Com	20	466	0	14	81	0.023	CO	No	CO	I
47	Previous SAH†	BB	9	88	0	26	8	0.030	RA	No	...	I

SCA indicates superior cerebellar artery; PCA, posterior cerebral artery; P.Com, posterior communicating artery; BB, basilar bifurcation; Ophit, ophthalmic carotid aneurysm; PICA, posterior-inferior cerebellar artery; A.Com, anterior communicating artery; CB, carotid bifurcation; Peric, pericallosal artery; MCA, middle cerebral artery; SAH, subarachnoid hemorrhage; CO, complete obliteration; RN, residual neck; RA, residual aneurysm; F, failure.

*Maximum sizes and volumes used to calculate activities/mm³ or packing densities may differ in these partially thrombose aneurysms.

†Patients with 1 to 4 recurrences after endovascular treatment.

TABLE 2. Risk Factors for Recurrences

Aneurysm ≥ 10 mm	21 (48%)
Wide neck >4 mm	21 (48%)
Ruptured aneurysm	18 (41%)
Residual aneurysm after treatment	9 (21%)
Recurrence after previous coiling	12 (27%)

was already a recurrence after 1 to 4 endovascular procedures.

Most lesions (43/44; 98%) had at least 1 risk factor for recurrence (previously identified and published⁸). Risk factors are detailed in Table 2.

Immediate Results

Forty of 44 aneurysms (91%) could be treated with radioactive coils. The lesion could not be treated with coils (radioactive or not) in 3 patients (7%) because the aneurysmal neck was too wide. In 2 patients coiling was possible only with coils selected outside the study kit. A significant proportion of lesions (17; 39%) were difficult to treat, necessitating the use of balloon-assisted techniques (6; 14%), adjunct devices such as an aneurysmal neck-bridge device (7; 16%), or additional techniques such as deliberate branch occlusions (4; 9%).

Angiographic results are summarized in Table 3. Initial angiographic results were satisfactory (complete occlusions or residual necks) in 75% of lesions.

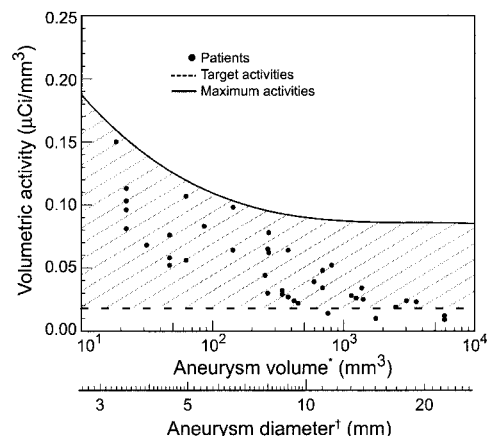
The target activities could be reached in 88% of lesions that could actually be coiled (35/40), and maximal activities were never exceeded. Total activities ranged from 1.72 to 80.9 μCi , for a mean of $20.13 \pm 20.80 \mu\text{Ci}$. Volumetric activities ranged from 0.01 to 0.15 $\mu\text{Ci}/\text{mm}^3$, for a mean of $0.06 \pm 0.04 \mu\text{Ci}/\text{mm}^3$. Activities for each lesion plotted according to target and maximal values are illustrated in the Figure. Lesions were treated with a mean of $107 \pm 109 \text{ cm}$ (range, 8 to 466 cm) of radioactive coils and $48 \pm 64 \text{ cm}$ (range, 2 to 210 cm) of nonradioactive coils. The mean packing density was $25 \pm 17\%$.

Working surfaces and materials used for the procedures were found free of radioactive contamination. Activities that were measured before coils were deployed and retrieved from aneurysms (because they were considered inappropriate) remained unchanged after the procedure. Urinary collections showed trace amounts of ^{32}P at <6 hours ($0.18 \pm 0.05 \mu\text{Ci}/\text{L}$) and at 24 hours ($0.02 \pm 0.01 \mu\text{Ci}/\text{L}$).

Rebleeding was prevented in all 18 patients with subarachnoid hemorrhage.

TABLE 3. Immediate and 6-Month Follow-Up Angiographic Results

	Immediate	6-Month Follow-Up
Complete occlusion	15 (34%)	16 (43%)
Residual neck	18 (41%)	13 (35%)
Residual aneurysm	8 (18%)	8 (23%)
Failure	3 (7%)	...
Total	44 (100%)	37 (100%)



Volumetric activities. Maximal volumetric activities derived from dose-point kernel method and Monte Carlo simulations are shown as a solid line. The dotted line is $0.018 \mu\text{Ci}/\text{mm}^3$.¹⁰ Actual activities and volume are shown as dots. *Volumes were estimated with the use of an ellipsoid model. †This scale shows corresponding diameters if volumes were spheres.

Procedural Complications

Thromboembolic complications occurred in 3 patients (7%). In 2 patients these complications were asymptomatic, but 1 patient suffered cerebellar and thalamic infarctions from deliberate occlusion of the posterior cerebral and superior cerebellar arteries in attempting to treat a giant aneurysm (patient 2; GOS grade IV).

One patient suffered transient increased dysarthria and hemiparesis immediately after treatment, interpreted as an increase in mass effect (patient 1), with resolution within a few days.

One patient had transient cortical blindness attributed to toxicity of contrast agent injected during angiographic monitoring of the procedure (patient 4).

Clinical and Angiographic Follow-Up

Overall, 35 patients (85%) had a good outcome (32 GOS grade I and 3 GOS grade II). Six patients (15%) had a bad outcome (4 GOS grade III, 1 GOS grade IV, and 1 GOS grade V). In 7 of a total of 9 patients with neurological deficits, these were sequelae from the initial subarachnoid hemorrhage or subsequent disease-related complications such as vasospasm (2 GOS grade II, 4 GOS grade III).

Late neurological events occurred in 2 patients. A 75-year-old patient died 10 months after treatment, with progressive neurological deterioration attributed to relentless mass effect from a giant superior cerebellar artery aneurysm and hydrocephalus not improved by ventricular drainage (patient 1). There was no autopsy.

Patient 9 presented 5 months after incomplete occlusion of a complex posterior communicating artery aneurysm with subarachnoid hemorrhage (Hunt and Hess grade II). Follow-up angiography showed a minor recurrence. The lesion was treated by surgical clipping with a good outcome (GOS grade II).

Angiographic follow-up studies at 6 to 12 months are available in 37 lesions, including 36 (90%) of those actually treated with radioactive coils. Absence of angiographic

follow-up was due to failures (3; 7% of lesions), refusal (3; 7%), and follow-up study planned but not yet performed (2; 5%). Results were stable in 25 lesions (69%). Recurrences (of any type) were found in 11 (31%) (95% CI, 18% to 47%), including 5 major recurrences (14%) (95% CI, 6% to 29%). According to our previous retrospective study,⁸ the characteristics of lesions, and the length of angiographic follow-up periods, we should have expected 16 recurrences, including 6 major ones.

There was no complication related to beta radiation during a mean follow-up of 10 months (range, 6 to 22 months). One-year follow-up imaging studies (MRI and CT scan) have yet to be performed in most patients.

Discussion

The first goal of this study was to assess the feasibility of the radioactive coil strategy. It was possible to reach target activities in >80% of lesions without exceeding arbitrarily fixed maximal values. This initial experience included many large and giant aneurysms, those requiring the widest variety and the largest number of coils per lesion. The fact that we could effectively reach the target total activity for most lesions is encouraging.

Accurate dosimetry is limited by the uncertainty of the coil geometry deployed inside the aneurysm volume. The rationale behind a target therapeutic activity hypothesizes that the clot formed between and over the coils cannot be recanalized if it is submitted to a sufficient dose of radiation.^{10–12} Since nonradioactive coils were allowed in this study to ensure the same safety as standard coil embolization, and because total activities have to be tailored to the size of the lesion, we defined the target therapeutic activity according to the volume of the aneurysm. This activity per cubic millimeter (0.018 $\mu\text{Ci}/\text{mm}^3$) derives from mathematical models applied to preclinical studies.^{10–12} The validity of this approach was then tested in animal models.¹¹ We have shown that the exact position of the radioactive source and potential interference from nonradioactive metallic devices, to a certain extent, are not critical. The important predictor of efficacy in the prevention of recanalization was the total activity per volume.¹¹ Thus, the interventionist aims at a target activity obtained by introducing a sufficient number of radioactive coils. The clinical feasibility of such a strategy was validated in a simulation based on retrospective clinical material.¹²

One important effect of selection bias was the inclusion of a majority of difficult lesions, necessitating more complex procedures at higher risks of complications unrelated to the use of radiation.¹⁸ Because a radioactive coil strategy does not change the mechanical properties of the coils, we did not expect and did not observe a difference in procedure-related complications. For the same reason and because nonradioactive coils could always be used if they were believed to be more appropriate in any circumstance, immediate angiographic results and packing densities were similar to those obtained in other series with similar selection bias for a large aneurysm with wide neck.^{8,18}

A second goal of this pilot study was to verify that there would be no added complication related to radiation. Radiation damage to nervous tissues may become manifest only

years after exposure, and longer follow-up periods will be valuable to exclude such events. Conventional radiotherapy has been associated with delayed brain injury in 0.04% to 0.4% of cases.^{19,20} Pertinent factors involved in increasing the risks of injury are a large total dose, a large irradiated volume, and a small number of treatment fractions given over a short period of time. Maximal doses given in one fraction by stereotaxic radiosurgery for arteriovenous malformations of the brain have been associated with higher risks, from 1% to 4%.^{21–23} Beta radiation minimizes risks because intrinsic safety factors include a small target volume (consisting of a thin rim of tissues around the coil mass), long treatment time, and, above all, low dose rates. Multiplying the number of fractions over a period of weeks is important to reduce risks of injury with conventional x-ray therapy. Beta radiation is in fact delivering the total dose at an ultra-low rate for the lifetime of the isotope. Thus, the risks are a small fraction of those rarely observed in conventional therapy. Another risk of conventional radiotherapy to the whole brain, estimated at 1.9% over 20 years, is the late development of a tumor.^{24,25} Carcinogenesis is not thought to be a relevant risk with local beta radiation because the amount of tissue exposed is much smaller, extending only a few millimeters outside the aneurysm volume. Although radioactive coil embolization is a new treatment, small activities, low penetration of beta radiation, short half-life, low-dose rate, and the fact that we have fixed maximum activities corresponding to therapeutic activities per volume classically used in the treatment of benign intracranial cysts will ensure that radiation injury to neighboring structures will be minimal or absent. A valuable safety study is, however, beyond the scope of the present work and would need to be integrated into a large-scale efficacy study.

For ethical reasons, we first offered this experimental radioactive strategy to patients harboring lesions at high risk of recurrence. We then widened inclusion criteria to be representative of the population treated by the endovascular approach, but selection bias persisted, with clinicians still recruiting patients in whom they expected a recurrence and thus a benefit. We previously identified aneurysmal size, neck size, the ruptured nature of the lesion, incomplete treatment, and length of follow-up period as risk factors associated with recurrences.⁸ The number of recurrences that were actually observed is within the expected range according to the logistic regression model resulting from this retrospective study. This model did not take into consideration previous recurrences as an added risk, a characteristic associated with 48% of major recurrences⁸ and present in 25% of lesions of the present report.

This pilot study was not designed to assess efficacy. Total numbers are small, CIs are wide, and recurrence rates that were observed are compatible with any hypothesis (success or failure in decreasing recurrences). Only a randomized study on a total of 500 patients (including acutely ruptured lesions in patients who may not survive to contribute to the primary end point) could verify whether a radioactive coil strategy could diminish recurrences, from an expected rate of 20% (of major recurrence) to 10%, with an α -error of 5% and a β -error of 20%. In our opinion, a more ambitious goal is not

realistic when one considers the frequency of lesions that are incompletely obliterated after treatment.^{6,8} Whether the biological effects of beta radiation will be sufficient to compensate for intrinsic limitations of coiling remains a concern.

Conclusion

Radioactive coil embolization of intracranial aneurysms is feasible. A randomized study comparing radioactive and nonradioactive coil embolization is the best way to assess the potential of beta radiation to improve long-term results of patients treated by endovascular techniques.

References

- Molyneux A, Kerr R, Stratton I, Sandercock P, Clarke M, Shrimpton J, Holman R. International Subarachnoid Aneurysm Trial (ISAT) Collaborative Group. International Subarachnoid Aneurysm Trial (ISAT) of neurosurgical clipping versus endovascular coiling in 2143 patients with ruptured intracranial aneurysms: a randomised trial. *Lancet*. 2002;360:1267–1274.
- Roy D, Milot G, Raymond J. Endovascular treatment of unruptured aneurysms. *Stroke*. 2001;32:1998–2004.
- Murayama Y, Vinuela F, Duckwiler GR, Gobin YP, Guglielmi G. Embolization of incidental cerebral aneurysms by using the Guglielmi detachable coil system. *J Neurosurg*. 1999;90:207–214.
- Johnston SC, Dudley RA, Gress DR, Ono L. Surgical and endovascular treatment of unruptured cerebral aneurysms at university hospitals. *Neurology*. 1999;52:1799–1805.
- Bederson JB, Awad IA, Wiebers DO, Piepgras D, Haley EC Jr, Brott T, Hademenos G, Chyatte D, Rosenwasser R, Caroselli C. Recommendations for the management of patients with unruptured intracranial aneurysms: a statement for healthcare professionals from the Stroke Council of the American Heart Association. *Stroke*. 2000;31:2742–2750.
- Hayakawa M, Murayama Y, Duckwiler GR, Gobin YP, Guglielmi G, Vinuela F. Natural history of the neck remnant of a cerebral aneurysm treated with the Guglielmi detachable coil system. *J Neurosurg*. 2000;93:561–568.
- Cognard C, Weill A, Spelle L, Piotin M, Castaings L, Rey A, Moret J. Long-term angiographic follow-up of 169 intracranial berry aneurysms occluded with detachable coils. *Radiology*. 1999;212:348–356.
- Raymond J, Guilbert F, Weill A, Georganos SA, Juravsky L, Lambert A, Lamoureux J, Chagnon M, Roy D. Long-term angiographic recurrences after selective endovascular treatment of aneurysms with detachable coils. *Stroke*. 2003;34:1398–1403.
- Ng P, Khangure MS, Phatouros CC, Bynevelt M, ApSimon H, McAuliffe W. Endovascular treatment of intracranial aneurysms with Guglielmi detachable coils: analysis of midterm angiographic and clinical outcomes. *Stroke*. 2002;33:210–217.
- Raymond J, Leblanc P, Desfaits AC, Salazkin I, Morel F, Janicki C, Roorda S. In situ beta radiation to prevent recanalization after coil embolization of cerebral aneurysms. *Stroke*. 2002;33:421–427.
- Raymond J, Leblanc P, Morel F, Salazkin I, Gevry G. Beta radiation and inhibition of recanalization after coil embolization of canine arteries and experimental aneurysms: how should radiation be delivered? *Stroke*. 2003;34:1262–1268.
- Raymond J, Leblanc P, Lambert A, Georganos SA, Guilbert F, Janicki C, Roorda S. Feasibility of radioactive embolization of intracranial aneurysms using ³²P-implanted coils. *Stroke*. 2003;34:1035–1037.
- Shapiro B, Fig LM, Gross MD. Intracavitary therapy of craniopharyngiomas. *Q J Nucl Med*. 1999;43:367–374.
- Bolch WE, Bouchet LG, Robertson JS, Wessels BW, Siegel JA, Howell RW, Erdi AK, Aydogan B, Costes S, Watson EE, et al. MIRD pamphlet No. 17: the dosimetry of non-uniform activity distributions: radionuclide S values at the voxel level. Medical Internal Radiation Dose Committee. *J Nucl Med*. 1999;40:11S–36S.
- Janicki C, Seuntjens J. Evaluation of the dose to cyst wall and to surrounding tissues in P-32 and Y-90 radiocolloid treatments of cysts using the dose-point-kernel and Monte-Carlo methods. *Med Phys*. 2002;29:1203.
- Raymond J, Roy D, Bojanowski M, Moudjian R, L'Esperance G. Endovascular treatment of acutely ruptured and unruptured aneurysms of the basilar bifurcation. *J Neurosurg*. 1997;86:211–219.
- Roy D, Raymond J, Bouthillier A, Bojanowski MW, Moudjian R, L'Esperance G. Endovascular treatment of ophthalmic segment aneurysms with Guglielmi detachable coils. *AJNR Am J Neuroradiol*. 1997;18:1207–1215.
- Raymond J, Guilbert F, Roy D. Neck-bridge device for endovascular treatment of wide-neck bifurcation aneurysms: initial experience. *Radiology*. 2001;221:318–326.
- Sheline GE, Wara WM, Smith V. Therapeutic irradiation and brain injury. *Int J Radiat Oncol Biol Phys*. 1980;6:1215–1228.
- Emami B, Lyman J, Brown A, Coia L, Goitein M, Munzenrider JE, Shank B, Solin LJ, Wesson M. Tolerance of normal tissue to therapeutic irradiation. *Int J Radiat Oncol Biol Phys*. 1991;21:109–122.
- Girkin CA, Comey CH, Lunsford LD, Goodman ML, Kline LB. Radiation optic neuropathy after stereotactic radiosurgery. *Ophthalmology*. 1997;104:1634–1643.
- Ganz JC, Backlund EO, Thorsen FA. The effects of gamma knife surgery of pituitary adenomas on tumor growth and endocrinopathies. *Stereotact Funct Neurosurg*. 1993;61:30–37.
- Jackson IM, Noren G. Role of gamma knife therapy in the management of pituitary tumors. *Endocrinol Metab Clin North Am*. 1999;28:133–142.
- Brada M, Ford D, Ashley S, Bliss JM, Crowley S, Mason M, Rajan B, Traish D. Risk of second brain tumour after conservative surgery and radiotherapy for pituitary adenoma. *BMJ*. 1992;304:1343–1346.
- Simmons NE, Laws ER Jr. Glioma occurrence after sellar irradiation: case report and review. *Neurosurgery*. 1998;42:172–178.